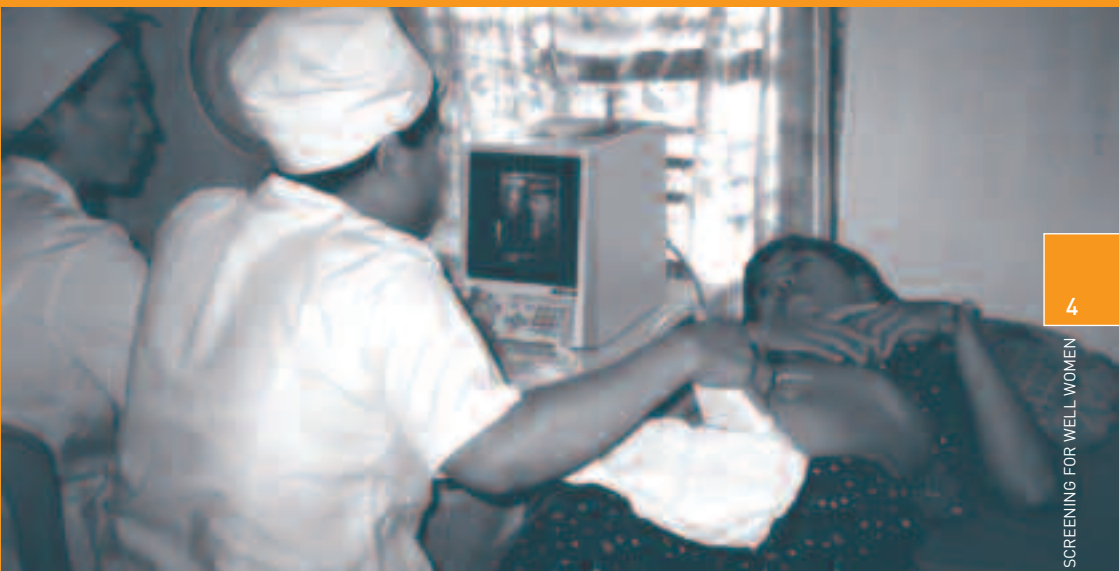

Photo: Fatiha Terki/Vietnam



4 REPRODUCTIVE HEALTH SCREENING FOR WELL WOMEN

4

REPRODUCTIVE HEALTH SCREENING FOR WELL WOMEN

1 Introduction

Health screening is an important aspect of health care, which promotes population and individual wellbeing by early recognition of treatable disease and identification of those individuals who are at higher than normal risk of developing a particular disease and might therefore benefit from closer follow-up.

Sexual and reproductive health (SRH)/family planning clinics often provide the most convenient opportunity for the reproductive health screening of well women. Where available, well-woman screening should be offered to all clients of SRH/family planning clinics, especially to those women with a risk factor (see section 6). However, the provision of SRH/family planning services should *not* be conditional on women accepting any kind of well-women screening services.

In general, population screening programmes should target diseases that are:

- Prevalent enough and cause a sufficient degree of morbidity and mortality to merit a large-scale screening programme.
- Detectable by relatively simple means.
- Amenable to early treatment.

2 Health conditions targeted by reproductive health screening

These conditions fall into three main groups:

- Reproductive tract infections (RTIs) and sexually transmitted infections (STIs).
- Cancer (breast, cervical, endometrial and ovarian).
- The menopause.

3 Who is eligible for reproductive health screening?

Ideally, reproductive health screening should be available to:

- All women who attend SRH/family planning clinics.
- All women in high-risk groups.
- All women who request a check up.

4 Who can provide reproductive health screening?

With appropriate training, subject to local regulations and practice, reproductive health screening may be provided by:

- Doctors.
- Nurses.
- Midwives.

5 Requisites for a successful reproductive health screening programme

Key actions needed to provide a successful well-woman screening programme in SRH/family planning clinics include the following:

- Ensure that the clinic setting is user-friendly and easily accessible to clients in terms of its location, times of opening, and administrative procedures. Fees charged, if any, should be affordable to the target population. The environment should impart a sense of warmth and privacy.
- Set out clear protocols and establish proper staff training and supervision to ensure that appropriate service standards are met. Emphasize skills in communication as well as in performing clinical tasks.
- Create an environment where clients trust all staff and feel comfortable in talking about any fears that they may have about their own physical and psychological wellbeing. Client confidentiality must be maintained.
- Put across the message of the importance of regular reproductive

health checks and screening procedures in terms that are understood by clients.

- Provide information through the distribution of educational pamphlets and the organization of health talks and demonstrations, with the use of appropriate audiovisual aids where available.
- Keep accurate and complete records, and plan regular follow-up so that clients are not lost after the visit.
- Ensure that specially trained health professionals can provide proper counselling of women found to have a disease.
- Establish channels for referral to specialist care and further management, and make the referral process as efficient and trouble-free as possible.

The provision of reproductive health screening in SRH/family planning clinics should not overwhelm their facilities or personnel such that some women are denied the SRH/family planning services they are looking for. On the other hand, when SRH/family planning clinics do provide reproductive health screening services, these should not be made conditional on the use of any form of contraception.

6 Reproductive health screening

Reproductive tract infections (RTIs) and sexually transmitted infections (STIs) are discussed in detail in chapter 13. In this chapter, discussion centres on general aspects of reproductive health screening, and factors of special relevance to gynaecological cancers and the menopause.

6.1 Taking a history

As with all consultations, it is important to take an adequate medical history. All the usual aspects of the medical and social history should be covered (see Box 4.1), including demographic data; relevant family history; past general medical history, with identification of present and past illnesses including diabetes mellitus, anaemia, or immunodepression; menstrual, gynaecological, obstetric contraceptive and sexual history, with discussion of RTIs/STIs, including HIV, pelvic inflammatory disease (PID) and risk factors to STI such as multiple partners; and social history.

Box 4.1-Medical and social aspects to be covered in the history

- *Demographic data:* Age, parity.
- *Family history:* Health of parents, siblings.
- *Medical history:* Previous illnesses or operations, history of blood transfusion, any current medications or treatments, any allergies.
- *Immunization history:* Rubella, hepatitis vaccination.
- *Menstrual history:* Date of last menstrual period, age of menarche, regularity of cycles, amount and duration of menstrual flow, presence and severity of associated symptoms such as dysmenorrhoea and premenstrual tension, details about any abnormal vaginal bleeding (For a menopausal or perimenopausal woman, the presence and severity of postmenopausal symptoms).
- *Gynaecological history:* Previous illnesses including infections, any current or recurrent symptoms, such as vaginal discharge or vulval itchiness, RTIs/STIs.
- *Obstetric history:* Dates and details of past pregnancies and deliveries.
- *Contraceptive history:* Methods ever used and any side-effects.
- *Sexual history:* Age at first intercourse, number of sexual partners, any sexual problems including dyspareunia and post-coital bleeding.
- *Social history:* Smoking and alcohol intake.

In the well-woman health screening setting, most clients will be symptom free, so it is necessary to ask each client specific questions to elicit possible early symptoms related to high-risk conditions that might not otherwise be volunteered (see Box 4.2 for questions in relation to relevant high-risk conditions).

Box 4.2-Risk factors for breast, cervical, endometrial and ovarian cancers*Breast cancer:*

- Age over 40 years.
- Family history of breast cancer, especially in a first-degree relative (mother/sister) who developed the disease before menopause.
- Early menarche or late menopause.
- Nulliparity or first pregnancy after the age of 30 years.
- History of atypical hyperplasia in the breast.
- High-fat diet and obesity.
- Had hormone replacement therapy (HRT) for 5 years or more.
- Never breast-fed.

Cervical cancer:

- Sexual intercourse before age 20 years.
- Multiple sexual partners.
- Infection with human papillomavirus (HPV).
- Cigarette smoking.
- History of sexually transmitted infections (STIs).

Endometrial cancer:

- Age over 50 years.
- Family history of endometrial cancer.
- Menstrual irregularity associated with anovulatory cycles.
- Late menopause.
- Nulliparity/infertility.
- Use of unopposed oestrogen.
- History of endometrial hyperplasia.
- History of diabetes mellitus and/or hypertension.
- High-fat diet, obesity.

Continued on following page

Box 4.2-continued*Ovarian cancer:*

- Age over 50 years.
- Family history of ovarian cancer, especially in a first-degree relative.
- Early menarche and late menopause.
- Nulliparity or first pregnancy after age 30 years.
- High-fat, low-fibre diet.

6.2 Physical examination

The physical examination will be guided by the history elicited, including the method of contraception chosen by the client, and should include general routine clinical examination, breast examination and pelvic examination. These procedures should be fully explained to the client in terms that are readily understood, and the client should be encouraged to relax and be reassured that the examination can be stopped at any time if she so requests. Male health workers or the client may request a chaperone for the physical examination.

General examination

Cover the following aspects in the general examination:

- General appearance; build; gait and posture; speech pattern.
- Body weight and height; body mass index (especially if obese).
- Blood pressure; pulse.
- Presence of pallor, jaundice, leg varicosities, ankle oedema, abnormal skin pigmentation or markings.
- Thyroid enlargement (ask the client to swallow); cervical and supraclavicular lymph nodes and other neck masses on palpation.
- Breath and heart sounds.
- Presence of abdominal scars, enlargement or tenderness of the liver, spleen or kidneys; any other abdominal mass (e.g., gravid uterus).
- Presence of inguinal lymph nodes.

6.2.1 Breast cancer screening

Guidance on the value of breast cancer screening programmes should take into consideration the needs and realities of resource-constrained settings. In these settings, the benefit of putting resources into breast cancer screening programmes should be weighed against the benefits of allocating them to other health services. The risks and benefits of screening will vary from setting to setting. The provision of follow-up services is crucial for effective screening programmes.

Mammography

The best currently available method for early detection of breast cancer is mammography combined with clinical breast examination. Where resources are available, regular mammography is usually offered to women aged 50-70. The frequency of mammography will depend on age-specific incidence rates and local health policy but is normally every 1-2 years. Current evidence does not show a survival benefit for mass screening for breast cancer and evidence on breast cancer mortality is inconclusive.

Clinical breast examination

When mammography is not available, clinical breast examination may be offered. At present, it is not possible to make evidence-based recommendations on which women should be examined or how often. However, it is prudent to offer clinical breast examination to women over 40 and those under 40 with other risk factors, which are primarily related to family history (eg, breast cancer in a first-degree relative).

The breasts should also be examined, with palpation of the axillae to detect abnormal masses or tenderness.

Inspection:

- Explain the procedure to the client and the reason for doing it.
- Make the client sit at the end of the examination table with her arms relaxed by her side. Ask her to remove her gown up to the waist.
- Observe the following:
 - Contour and symmetry of breasts.
 - Any dimpling, swelling, discoloration and flattening of skin.
 - Nipple retraction or any discharge.

Palpation:

- Ask the client to lie down on her back, remove the gown from one breast and put her hand behind her head on that side.
- Use the pads of the three middle fingers. Wear gloves if there are open sores or any discharge.
- Begin palpation at the junction of the clavicle and sternum. Use small circular movements and vary the pressure applied by the fingers in three grades: light for the superficial layer, moderate for the middle layer and firm for deep layers.
- Palpate the breast in overlapping vertical strips and continue until the entire breast, including the axillary tail, has been covered.
- Palpate around areola and the depression under the nipple. Press the nipple between the thumb and index finger to see if there is any discharge.
- Lower the client's arm and palpate for axillary lymph glands.
- Repeat the same on the other side.

Instruction about breast self-awareness

Breast self-examination does not decrease mortality and should no longer be recommended as a screening tool. However, women should be "breast aware"; and a woman who finds an abnormality in the course of her regular activities should have it checked by a trained professional.

Service providers need to instruct the client about breast self-awareness. Explain to her that breast cancer is one of the most common forms of cancer in women, and in its early stages it rarely causes symptoms and often first presents as a painless breast lump or a change in the appearance or feel of the breasts. Some breast cancers are first identified by women themselves, and the earlier breast cancer is detected, the higher the cure rate.

Clients should be told to look for the following warning signs:

- Any lump or thickening in the breasts, whatever the size.
- Any change in the appearance or shape of the breasts.
- Alteration in the position or level of the nipples.
- Dimpling of the skin surface.

- Retracted nipples.
- Discharge or bleeding from the nipples.
- Puckering of the skin surface like that of an orange (*p'eanu d'orange*).

Tell the client to go to a doctor to have a thorough examination if she finds any unusual changes in her breasts.

6.2.2 Pelvic examination

Pelvic examination should be offered to women as part of reproductive health screening and should only be carried out if the woman accepts it.

If this is the client's first gynaecological examination, it is particularly important to put her at ease by a careful explanation of the procedure involved and the reasons for doing it. Encourage her to relax, and reassure her that the examination can be stopped at any time if she so requests.

Pelvic examination wearing gloves (not necessarily sterile) must be done in all women requesting an IUD, surgical sterilization or diaphragm insertion, and it should be offered to all women who visit the clinic for the first time and are aged 18 years or older or have been sexually active before 18 years of age.

During the pelvic examination:

- Ask the client to lie in the supine position with her legs bent at the knees, with the knees apart and the ankles together.
- Inspect the external genitalia, including the labia, prepuce, clitoris, urethral opening, perineum and anal opening. (If there is a history of vaginal prolapse or urinary stress incontinence, the client should be asked to strain with a full bladder to see if any cystocoele, rectocoele or leakage of urine is found).
- Palpate the vulva for tenderness and/or masses, particularly around Bartholin's glands.
- Ensure an adequate, adjustable light source.
- Insert a vaginal speculum of the appropriate size. In general, a larger instrument will be needed for a multiparous woman with lax vaginal walls, and a narrow speculum should be used for a nulliparous woman. The most commonly used models are the bivalve Cusco's and Graves'

speculum or the Sims' speculum. Water may be used for lubrication: if a cervical smear is to be taken (see section 7), KY jelly must not be used, but in other circumstances application of a very small amount may be helpful.

- Inspect the vagina for rugae, discharge (noting its colour, amount, consistency and odour) and any protruding mass. If indicated and laboratory facilities are available, a vaginal swab can be obtained from the fornices for bacterial culture.
- Expose the cervix and inspect its appearance, the presence of any erosion or cyst, any masses, or contact bleeding. A cervical smear may be obtained from the squamo-columnar epithelium junction between the ectocervix and the endocervix (see section 7). If indicated (e.g., in a client with suspected pelvic inflammatory disease or at high risk of STIs), take an endocervical swab for culture.
- Withdraw the speculum and perform a bimanual examination, using KY jelly.
- With the index and middle fingers in the vagina, assess the vaginal tone.
- Feel the consistency of the cervix and note any pelvic tenderness on moving the cervix from side to side.
- Place the other hand suprapubically and palpate the uterus between two hands, noting its size, position, regularity, and any tenderness.
- Palpate each lateral fornix for abnormal masses or tenderness. Assess any masses detected for size, consistency, position, and mobility.
- A rectovaginal examination is not routinely carried out, but may be indicated if the client has symptoms and/or signs of pelvic tumour or endometriosis. With the index finger in the vagina and the middle finger of the same hand in the rectum, palpate the uterosacral ligaments and rectovaginal septum for nodularity and other lesions.

A bimanual pelvic examination is not necessarily indicated after routine cervical smear screening, but should always be performed in the presence of pelvic symptoms (see Box 4.3).

Box 4.3-Pelvic symptoms indicating a need for bimanual pelvic examination

- Very heavy or painful periods.
- Intermenstrual bleeding.
- Urinary symptoms.
- Abdominal swelling.
- Lower abdominal pain or discomfort.
- Dyspareunia (pain on sexual intercourse).

Remember at all times during the physical examination that the presence of abnormal vaginal discharge and foul smelling fishy or musty odour is suggestive of bacterial vaginosis and trichomonas vaginalis (see chapter 13 for discussion of the management of RTIs and STIs).

6.3 Other investigations

Urinalysis

Some clinics routinely do simple dipstick analysis to detect sugar, protein, blood and bilirubin.

Laboratory investigations

Some clinics may have their own laboratories, whereas others may need to send samples or refer clients for further testing. In some clients the following investigations may be indicated by the history or physical examination:

- *Haematology*: Haemoglobin, full blood count, clotting studies.
- *Biochemistry*: Renal function tests, liver function tests, fasting sugar, lipid profile, iron status.
- *Immunochemistry*: Syphilis serology, rubella and hepatitis serology, HIV antibody status (see chapter 14); hormone concentrations.
- *Microbiology*: Culture and sensitivity tests (particularly useful in cases of suspected RTIs/STIs (see chapter 13).

Ultrasonography

The use of routine ultrasound examination in early detection of pelvic masses, especially ovarian tumours, has not been universally adopted - mainly for logistical reasons. Staff must be adequately skilled and the equipment of sufficient resolution so as not to miss small symptomless lesions. Although ultrasonography may not be routinely available in the setting of an SRH/family planning clinic, there should be an established channel for the referral for further investigation of women in whom a pelvic mass has been detected on pelvic examination.

Endometrial biopsy

Women at high risk of endometrial cancer (see Box 4.2) and those with dysfunctional perimenopausal bleeding may be referred for endometrial sampling. Various techniques are available, including aspiration cytology and curettage.

Bone densitometry

Measurement of bone density may form part of the assessment of women being considered for hormone replacement therapy (HRT).

6.4 Frequency of reproductive health screening for well women

The age at which women should begin to have regular gynaecological examinations for the purposes of health screening, the interval between subsequent visits, and the age at which such screening programmes should stop depend on the availability of resources (e.g., clinic personnel, time, facilities) and on the presence or absence of risk factors in individual clients.

As noted above in specific relation to mammography, the provision of screening services is influenced by weighing the medical benefit appropriately against the economic and social costs of the examination, and different countries may come to different conclusions (see section 6.2.1).

In any discussion of recommended intervals for any screening programme, it should always be borne in mind that these are minimum standards; high-risk individuals may need to be screened more frequently, and if symptoms develop between screening intervals they should, of course, be dealt with appropriately. For gynaecological conditions, the existence of SRH/family planning clinics enables these services to be readily available (see section 7).

6.5 Other issues to consider during reproductive health screening

Reproductive health screening can also represent an opportunity to enforce proactively messages in relation to sexual health and healthy lifestyle issues. The latter are considered in section 8, but are generally applicable at all ages.

7 Cervical cancer screening

Cervical cancer screening may take place during the pelvic examination phase of reproductive health screening. The two techniques are:

1) Cervical cytology, involving:

- Obtaining an adequate cervical smear;
- Fixing the smear; *and*
- Laboratory processing and examination of the smear.

Cervical cytology does offer an indirect way to diagnose human papillomavirus (HPV) infection by means of highly specific and very sensitive tests for HPV DNA (e.g., by use of the polymerase chain reaction or hybrid 11 capture), but these techniques are very expensive and not widely available.

Although obtaining cervical smears for the purposes of screening for cervical cancer is an integral part of reproductive health screening, the particular features of this process are dealt with here in a separate section for ease of cross-reference. Other features discussed earlier in this chapter also apply to cervical cancer screening programmes.

Exfoliative cytology

Exfoliative cytology is the study of cells that have been shed by various membranes or epithelia, which can be collected, spread onto slides, and the resulting smears stained and examined under the microscope. In clinical practice, surfaces are usually scraped to provide cells for study. In the case of cervical cytology, examination of these cells shows whether the cervical epithelial lining is normal, inflamed, or has evidence of cervical intra-epithelial neoplasia (CIN) or carcinoma. The purpose of cervical cancer screening programmes is to detect cervical cancers from premalignant lesions, when the cure rate for intervention is very high.

Cervical cytology (pap screening)

Cervical cytology is currently the best available method for the detection of pre-malignant and malignant disease of the cervix. When routine pap screening is available it should start 2-3 years after the onset of sexual activity and be repeated every 1-3 years. When only limited pap screening is available, it should at the very least be offered at around the age of 35 to all women who have ever been sexually active.

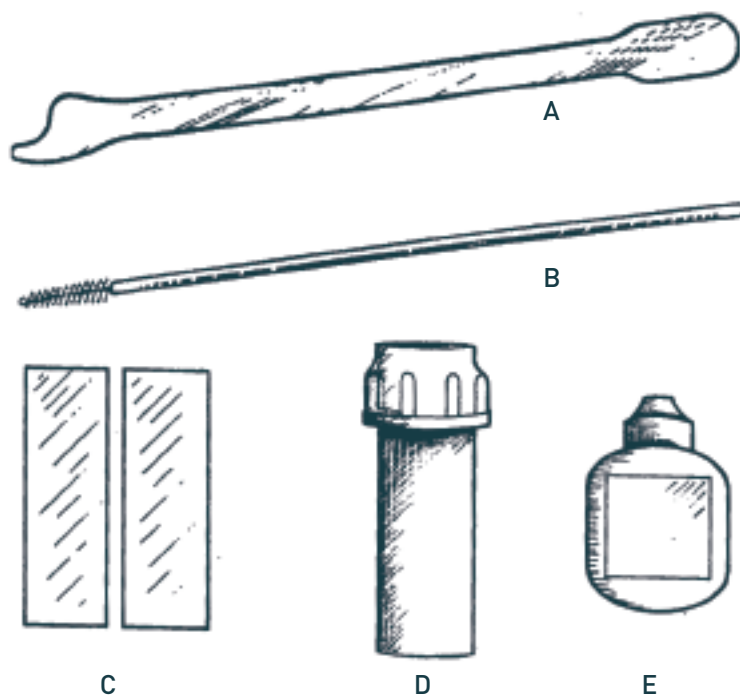
Screening for cervical cancer by means of cervical smears should be available in all reproductive health screening programmes. Ensure that there:

- Is access to reliable laboratory facilities for the cytological analysis of cervical smears;
- Are adequate facilities for tracing women with a positive result; and
- Are adequate facilities for referral.

The extra equipment needed for taking a cervical smear during the pelvic examination (see Figure 4.1) consists of:

- Aylesbury spatula.
- Endocervical brush.
- Glass slides.
- Fixing jar or spray fixative.
- Hard pencil.

Figure 4.1 Equipment required for cervical smear



A = Aylesbury spatula; B = Cytobrush; C = Glass slides; D = Fixing jar; E = Spray fixative.

Before collecting the cervical smear the essential equipment for making and fixing the smear should be assembled and preferably laid out on a tray. Slides should be carefully labelled with a hard pencil on the ground glass edge (or etched; ink will dissolve during processing). A simple information checklist for cervical cancer screening is shown in Box 4.4.

Box 4.4-Information checklist for cervical cancer screening

- First name and surname.
- Age.
- Clinic registration number.
- Date of last menstrual period (LMP).
- Length of menstrual cycle.
- Pregnancy status.
- Number of previous pregnancies.
- Date and type of previous gynaecological operations.
- Any history of radiotherapy treatment.
- Results of previous smears.
- Symptoms (if any).
- Any intrauterine device (IUD) fitted.
- Any oral contraceptives or other hormones taken currently or previously.

Site of collection

Material for cytological examination may be collected from the:

- Posterior, anterior, or lateral fornix of the vagina (for evidence of endometrial or endocervical adenocarcinoma).
- Ectocervix and squamo-columnar junction.
- Endocervical canal.
- Upper third of the lateral vaginal wall (for evidence of endometrial or endocervical adenocarcinoma).

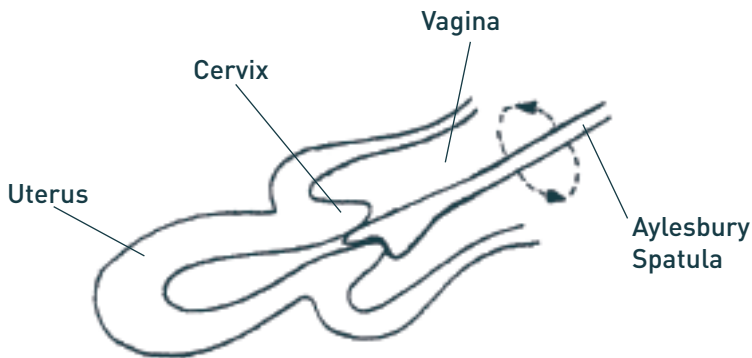
The choice of site and technique depends largely on the facilities available and the purpose of the examination. Most smears from the female genital tract are for the detection of cervical lesions, and for this purpose it is sufficient to collect material from the ectocervix, squamo-columnar junction, and endocervical canal (Exfoliative cytology for early detection of endometrial or endocervical adenocarcinoma is insensitive and unreliable).

Collection of the cervical smear

With the cervix exposed by an unlubricated speculum:

- Lightly scrape the ectocervix, any area that appears abnormal (e.g., an erosion) and the squamo-columnar junction between the ectocervix and endocervix, with the shaped end of the spatula (see Figure 4.2).

Figure 4.2 Scraping the squamo-columnar junction of the cervix



- Always scrape the full circumference of the squamo-columnar junction. When the squamo-columnar junction is well exposed, as in some multiparous women, better results are obtained with a larger spatula or by using the flatter end instead of the shaped end for scraping.
- Withdraw the spatula carefully from the vagina with the speculum still holding the walls apart.
- Place the scrapings immediately on one or two glass slides kept in readiness.
- Spread the secretions evenly over the previously prepared and labelled glass slide (see Figure 4.3):
 - Apply the spatula flat onto the slide and transfer the sample by a lengthwise sweep;
 - Repeat with the other side of the spatula (a circular or zigzag motion may be more effective in transferring the material);
 - Ensure that all the material is removed from both sides of the spatula; any material clinging to the spatula can be removed by scraping the

- spatula on the edge of the slide;
- Break up any lumps by exerting a little pressure with the spatula;
- If using a brush, spread the sample on the slide with a gentle rolling motion.
- Remember that speed is essential because air drying damages the cells in the smear and interferes with their staining properties and cytological interpretation.
- Fix the slides while the smears are still wet.
- Immerse the slides in jars filled with fixing fluid, or spray them with a commercial spray fixative (see Figure 4.4). Spraying is probably better and simpler, but sprays are expensive and not always readily available.
- Remove the speculum from the vagina after the smears have been fixed.

Figure 4.3 Spreading the cervical scrapings onto a glass slide



A single slide is almost always sufficient, but if there is a large amount of material a second slide may be needed. If only a scanty sample is obtained, a second scrape may be indicated. If two samples (e.g., scrape and brush or two scrape samples) are spread on one slide, the first sample should be fixed before the second sample is obtained.

Fix the slides immediately while the smears are still wet to stop them drying in the air. Rapid fixation is especially important for smears that contain blood and for smears from postmenopausal women, which dry very quickly.

Fixing in fluid

Suitable containers for fixing fluids are clean jam or honey jars and commercially available Coplin jars made of glass or plastic. When jam or honey jars are used, no more than one pair of slides should be immersed in each jar. Coplin jars can take up to five pairs of slides; these slides should be placed back to back (smear-carrying sides outwards) into the grooves of the fixing jar.

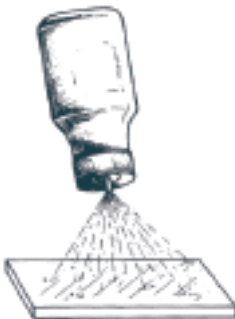Fixing fluids commonly used are various alcohols (e.g., 95% ethyl alcohol, methyl alcohol, isopropyl alcohol) or mixtures of different alcohols, such as three parts of 95% ethyl alcohol with seven parts of tertiary butyl alcohol.

The slides should remain in fixative for at least 15 minutes, but may be left there for as long as 7 or even 10 days without deterioration.

Spray fixation

Spray fixation gives excellent results and overall is much simpler and more economical, with savings in both time and equipment. The spray fixative must be spread evenly over the whole of the smeared area on the slide (see Figure 4.4).

Figure 4.4 Spray-fixing smear



The spray must not be held closer than 15 cm from the slide or it may tend to wash the specimen away. The various spray fixatives marketed contain an aerosol agent and different mixtures of alcohol, acetic acid, or ethylene or propylene glycol. Once spray-fixed slides are dry (usually within 10 minutes), they can be dispatched to the laboratory for staining directly without additional measures. Commercially available spray

fixatives are relatively expensive; ordinary hair sprays are as effective and are considerably cheaper.

Staining

After adequate fixation, the slides are ready for staining. The staining procedure requires laboratory facilities and should be carried out by a trained technician. When such facilities are not available, it may be necessary to dispatch the slides to a laboratory for further processing. For transportation, slides fixed in fluid should be removed from the fixing jars after adequate fixation and dried in the air. Dry fixed slides should be sent to the laboratory in flat cardboard or wooden boxes. On arrival in the laboratory they will be resuspended in fixative and stained. This process often involves use of Papanicolaou stain, based on aqueous haematoxylin with multiple counterstaining dyes in 95% ethyl alcohol, which gives great transparency and delicacy of detail for examination by a skilled cytologist—hence the term Papanicolaou (or Pap) smear.

Errors in smear taking and processing

Typical causes of error in smear taking and processing are shown in Box 4.5.

Other aspects of reproductive health screening programmes related to cervical cancer screening are discussed earlier in this chapter.

Box 4.5-Causes of error in smear taking and processing

- Cervix not visualized adequately.
- Cervix not scraped firmly enough.
- Transformation zone not completely scraped.
- Material collected from wrong site (e.g., by scraping posterior vaginal wall instead of cervix).
- Slides insufficiently cleaned or degreased before use.
- Material incompletely transferred from spatula to slide.
- Sample poorly spread (too thick, too thin or distortion from excessive pressure).
- Air drying before fixation or during the staining procedure.
- Insufficient fixation (time too short or alcohol too weak).
- Incorrect staining (e.g., incorrect staining time, insufficient dehydration or mistakes in preparation of the stains).
- Smear consists mainly of blood or purulent exudates.

2) Direct visual inspection of the cervix

If pap screening is not available, visual inspection of the cervix should be offered. It should start 2-3 years after the onset of sexual activity and be repeated every 1-3 years.

In this simple test, during pelvic examination the cervix is visualized, washed with normal saline, inspected, and then washed with a solution of 3-5% acetic acid (e.g., vinegar) and inspected again after 1 minute to identify areas of acetowhitening suggestive of precancerous lesions by direct vision. It can be used for cervical screening where cost is a major consideration and cervical smear testing cannot be offered to the whole of a large population. In such circumstances the acetic acid test is held to be negative if no area of acetowhitening can be seen, and the client can be followed up at the normal screening interval, or earlier if symptoms develop. If infection is suspected, a swab should be taken and if confirmed it should be treated accordingly.

The extra equipment needed for direct visual inspection of the cervix during the pelvic examination consists of:

- Normal saline.
- A syringe for lavage.
- Acetic acid 3-5%.
- A bowl.

Do not perform the examination if the client is having her menstrual period or using intravaginal medication; ask her to come back after menstruation or treatment.

If acetowhitening is seen (a positive acetic acid test) on direct visual examination, with no evidence of infection, a cervical smear should be taken. If cervical cytological examination is not available, colposcopy, cryotherapy or loop electrosurgical excision could be considered – but may also not be available in such circumstances. Referral where further investigation and treatment can be carried out is indicated.

8 The menopause

Although strictly speaking not part of reproductive health screening or SRH/family planning services, the menopause is also discussed here. Apart from the gynaecological malignancies already mentioned, conditions associated with the menopause are increasingly gaining the attention of providers of health care, especially in developed countries, because of their potential effects on the physical and psychological wellbeing of many otherwise healthy women. The menopause is associated not only with short-term acute symptoms that may cause women discomfort and distress, but also, and more importantly, with long-term complications (particularly osteoporosis and cardiovascular disease, major causes of mortality and morbidity among postmenopausal women) that have a profound effect on the general health status of and cost of health care in the community. Screening women who are at high risk of developing these long-term complications, and advising them accordingly, forms an important function of reproductive health care. Clinical features of the menopause are shown in Box 4.6.

Box 4.6-Clinical features of the menopause

- Amenorrhoea.
- Hot flushes.
- Mammary atrophy.
- Atrophic vaginitis.
- Pelvic floor atrophy.
- Osteoporosis.

Counsel women about ways in which they can improve their overall health and quality of life by following a healthy lifestyle and eating a balanced diet. Particular points include:

- *Smoking*: Counsel women who do smoke about the hazards of smoking and encourage them to give up the habit.
- *Exercise*: Regular exercise (including swimming and aerobic exercises) promotes cardiovascular health; weight-bearing physical activity (such as brisk walking) slows down bone loss and stimulates regeneration of bone tissue. Therefore recommend moderate exercise three or four times each week.
- *Diet*: Encourage clients to have a balanced diet. This should be low in saturated fats, sugar and salt; include plenty of fresh fruit, vegetables, whole grain and fibre; and contain sufficient protein, vitamins and minerals.
- *Weight*: Monitor weight and note gains or losses; aim to avoid obesity.
- *Stress*: Advise clients to avoid unnecessary stress.
- *Alcohol*: Suggest that clients limit alcohol intake to no more than two units (one to two drinks) daily.

For women at high risk of osteoporosis (see Box 4.7), a calcium supplement (e.g., 1,000 mg daily) or other drug treatment (e.g., with vitamin D or a bisphosphonate) may be considered appropriate. For women at high risk of osteoporosis and/or with severe menopausal symptoms, hormone replacement therapy (HRT) may be considered.

Such interventions should be tailored to availability, feasibility, and individual circumstances, and must take account of the latest available evidence in relation to costs, potential benefits, side-effects and contraindications.

Box 4.7-Risk factors for postmenopausal osteoporosis

- Early age of menopause (idiopathic or due to ovarian ablation from surgery or irradiation).
- Thin build, fair complexion.
- Family history of osteoporosis.
- Smoking/excess alcohol intake.
- Sedentary lifestyle due to lack of exercise or chronic illness.
- Use of corticosteroids.

